

Reorganization of Cerebral Blood Supply After Radiation Therapy for Pharyngeal Carcinoma

Morteza Alibakhshi Kenari

Department of Medical Sciences and Health Sciences, University of Sari, Iran

***Correspondence to:** Dr. Morteza Alibakhshi Kenari, Department of Medical Sciences and Health Sciences, University of Sari, Iran.

Received: 20 October 2018

Published: 17 December 2018

Copyright

© 2018 Dr. Morteza Alibakhshi Kenari. This is an open access article distributed under the Creative Commons Attribution License, which permits unrestricted use, distribution, and reproduction in any medium, provided the original work is properly cited.

Keywords: *Radiation; Carotid Occlusion; Collaterals; Brain Perfusion; Carotid Calcifications; Pharyngeal Carcinoma; Cerebral Blood Supply*

Abstract

A case of radiation-induced occlusion of both internal carotid arteries is presented. A 58-year-old man with history of surgical treatment for oropharyngeal carcinoma followed by radiotherapy 5 years ago, presented with a right-sided fronto-temporo-parietal infarction as a result of insufficient cerebral blood supply. Angiography revealed occlusion of both internal carotid arteries and a right-sided occlusion of common carotid artery. We describe an unusually efficient reorganization of his cerebral blood supply.

Introduction

Radiation therapy for facio-laryngeal malignancies endangers vascular walls of neck arteries. Attention should be paid to stenotic processes and their timely treatment.

Case Report

A 58-years old patient was brought by ambulance to department of neurology for having suffered sudden loss of consciousness of about 1minute duration. On arrival he was already void of any subjective problem. The neurological examination revealed small bruises in the face as consequences of his fall, assymetry of the mandible due to the resection of its right wing along with the treatment of pharyngeal carcinoma. A mild weakness of the left extremities combined with left-sided pyramidal irritation and unstable gait was considered a consequence of an infarction in the right hemisphere. Alcoholaemia of 1,95g/l was revealed and WBC count was increased to 13,2 and 18,9 respectively. The patient was a heavy smoker

In personal history the patient had lateral pharyngotomy, partial mandibulectomy and radical neck dissection on the right side for carcinoma of the right tonsill 5 years ago, followed by chemotherapy and fractionated radiotherapy by 70/2Gy. Two years ago the patient suffered a myocardial infarction.

The surprising phenomenon was our finding, that the patient was living with both internal carotid arteries (ICA) occluded and moreover on the right also with occlusion of the common carotid artery (CCA). His cerebral blood supply reacted to the advancing radiation induced arterial thrombosis on the neck by development of very extensive collaterals. The missing blood flow in carotid arteries demonstrates Fig. 1. These occlusions were elicited by extreme calcifications in carotid bifurcation on both sides (Fig. 2.).

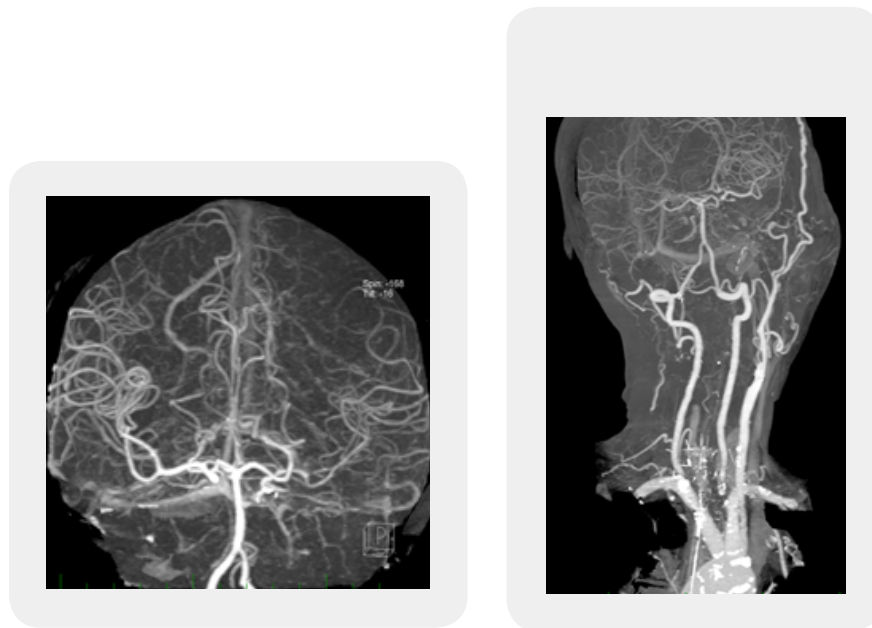


Figure 1: Occlusion of the common carotid artery on the right and of the internal carotid artery on the left. Despite this a solid general brain perfusion is preserved. Hypertrophic superior temporal superficial artery on the left.

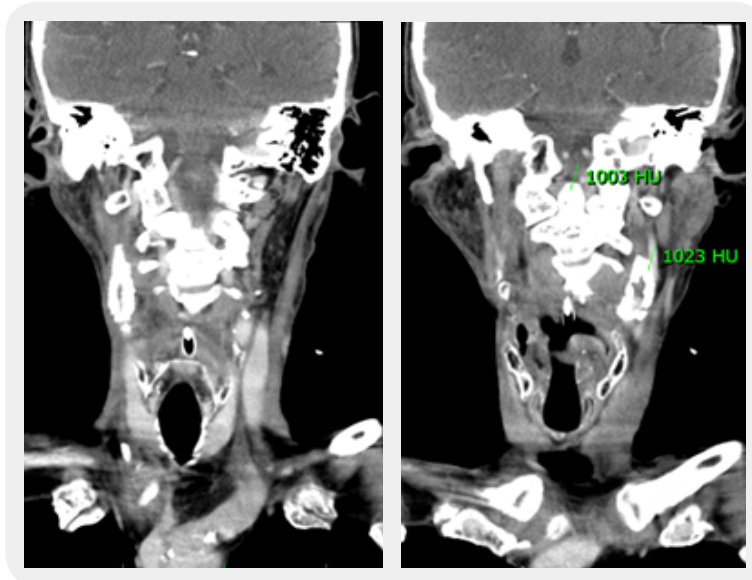


Figure 2: Both carotid bifurcations are severely calcified. The density of the left bulbous part surpasses by its 1023 Hounsfield units that of the dens epistrophei (making 1003 HU).

The motiv for our demonstration of the patient was an extraordinary reorganization of cerebral blood supply. The strong insufficiency of cerebral blood supply due to the gradually narrowing carotid lumen evoked a slowly increasing hypertrophy of the left external carotid, most prominently in the temporal superficial artery (Fig. 1 and 3.). This artery did however not supply the expected left ophthalmic artery but the right one. Since on the right side the external carotid artery has been compromised by the surgery, there were no resources for a similar compensation. As a result the left ophthalmic artery found its supply from the hypertrophic maxillar artery left and the right ophthalmic artery obtained its supply from the contralateral left hypertrophic temporal superficial artery (Fig.3). On Doppler ultrasound both ophthalmic arteries as well as their tributaries, supratrochlear arteries, were detected with retrograde blood flow.

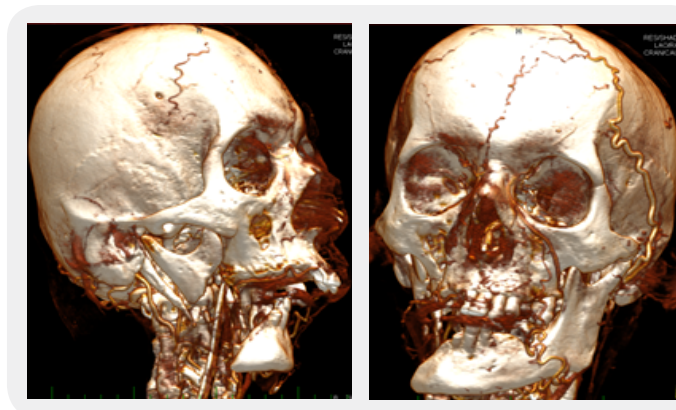


Figure 3: Missing carotid supply of the right splanchnocranium. Hypertrophic temporal superficial artery on the left, feeding the right a. dorsalis nasi and the ophthalmic artery. The left ophthalmic artery is supplied by the left maxillar artery. Huge nasal collaterals support the cerebral blood supply via the ethmoidal branches to the ophthalmic artery.

All the attempts of the collaterals using the ophthalmic arteries would have still hardly suffice, if not also the posterior circulation would have taken part in these new arrangements. The robust vertebral arteries appeared to feed the basilar artery (BA) so profusely, that the systolic blood velocity by Doppler ultrasound was found in VA 257cm/sec (4 times that of normal healthy velocity, Fig 4) and that of the BA made 121cm/sec in systole and 57cm/sec in the diastole.

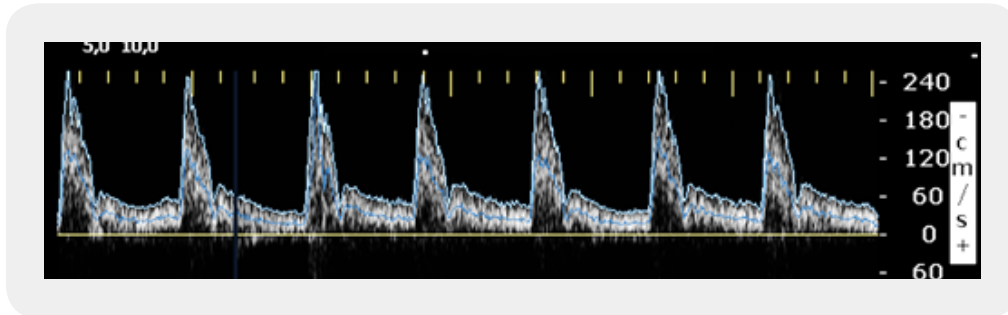


Figure 4: Very high systolic velocities in vertebral arteries (up to 257cm/sec) compensating the carotid failure via posterior communicating arteries in the circle of Willis.

The general lack of blood supply resulted on the day of admission into a right-sided fronto-temporo-parietal infarction, revealed by DWI on the first day and by CT on the second day. After a partial improvement in hospital the patient was transferred into a Home for seniors, where he died 5 months later.

Discussion

The success of oncological treatment in oropharyngeal carcinoma in recent decades allows for longer survival of affected patients. Since radiotherapy is a substantial component of this strategy, its consequences are getting more time to become apparent. Subsequent carotid stenoses, radiation induced calcifications and vascular injury in general receive increasing attention.

The radiation treatment is known to increase the intima-media thickness and eventually produce arterial stenosis. Thus ischaemic cerebral lesions belong to the most severe complications of head and neck radiation. The incidence of carotid stenosis in persons irradiated for nasopharyngeal carcinoma was found four times higher compared to patients treated without radiation [1]. Some other studies found even higher incidence in proportion to people without radiation. Cheng *et al* found it for instance six times higher as in other tumors and after 5 years from the radiation treatment even fifteen times higher [2]. The Medline and Pub Med-based review reported incidence of significant carotid stenosis following head and neck irradiation ranging from 30% to 50% [3]. Other studies dealing with this issue found significant stenosis in 18-40% of patients at 7,5 to 10 years after the treatment. Brown with co-authors have reported stenosis in 30% of patients treated with radiotherapy, but only in 5.6% of subjects without radiotherapy [4].

The endothelial cells are sensitive to radiation exposure and being disrupted or even torn off, they permit the denuded collagen to attract thrombocytes and provide a base for thrombus. Besides fibrin components permeate the arterial wall, causing the artery to become stiffer, not collaborating any more in the pulse wave.

The luminal narrowing follows [5]. Another place of radiation induced damage are the microvessels of the adventitia. Vasa vasorum are being occluded and ischaemic distress of the wall compromises lamina elastica and tunica media. Progression of atherosclerosis is also counted to the most probable mechanisms of the stenotic development [6]. Some studies were concerned mainly with the intima-media thickness (IMT). They found, that the IMT, as a good indicator of the atherosclerotic severity, increased in a linear manner with the interval after radiotherapy. Moreover 36,2% of checked persons after nasopharyngeal carcinoma had carotid plaques. The cut-off values for age and duration after radiotherapy were 52,5 years and 42,5 months [7]. The authors could conclude, that radiation induced vasculopathy is a dynamic and progressive process following the late radiation effects.

The carotid arteries are not the single vascular structure being damaged. Along with 77,5% of affections suffered on the common and the internal carotid artery in one study, also 7% of radiation injury were found on vertebral arteries.

Conclusion

The development of stenotic and finally occlusive processes on the neck arteries puts the patient into a risk of insufficient cerebral blood supply. As shown in our patient the capacity for development of collateral pathways is fascinating. When a stenosis left unrecognized, the patient could not be offered further medical support. In our case it would have been of big advantage, if the stenoses would have been discovered in time, allowing for interfering with recanalization technics. The postradiation character of the stenosis often prioritizes an intraarterial stenting over the otherwise preferential carotid endarterectomy. Anyway, securing a proper cerebral blood supply is a key concern in this sort of patients.

This simplified 3D method for AV measurement achieves a high accuracy and reproducibility. The results of this simplified method more strongly correlate with the highly reliable results obtained by the 3D modeling software than two previously established cross-sectional CT methods. Utilizing this simplified method may also be cost effective compared with 3D modeling software, which requires advanced computer console devices. Where there is no access to measurements of 3D reconstruction models in the clinical environment, this simplified method is appropriate and practical.

Bibliography

1. Gelaw, B. & Mengistu, Y. (2008). The prevalence of HIV, HCV and Malaria parasites among blood donors in Amahara and Tigray regional states. *Ethiop J Health Dev.*, 22, 3-7.
2. Amidu, N., Alhassan, A., Obirikorang, C., Feglo, P., Majeed, S. F., Piwon, N., *et al.* (2012). Sero-prevalence of hepatitis B surface (HBsAg) antigen in three densely populated communities in Kumasi, Ghana. *J Med and Biomed Sci.*, 1(2), 59-65.
3. Eophodia, M. (2011). Genotyping and molecular characterization of hepatitis B virus from HIV infected individuals in southern Africa. *Johansberg*, 7(9), 2-3.

4. Hughes J & Mahy B. (1998). Recommendations for prevention and control of hepatitis C virus infection and HCV-related chronic disease. CDC. *MMWR Recomm Rep.*, 47, 1-39.
5. Thaiar Kadhum, F. A. (1987). Sero epidemiological and molecular study of HBV in Al-rusafa sector of Baghdad. 30-34.
6. Held, P. J., Brunner, F., Odaka, M. *et al.* (1990). Five year survival for end-stage renal disease patients in the United States, Europe and Japan, 1982 to 1987. *Am J Kidney Dis.*, 15(5), 451-457.
7. Schon, S. (1996). Swedish registry for active treatment of uremia, Department of Nephrology, Skaraborgs Hospital.